

See discussions, stats, and author profiles for this publication at: <https://www.researchgate.net/publication/296671257>

A Case of Hepatotoxicity Related to Kombucha Tea Consumption

Article in *South Dakota journal of medicine* · January 2016

CITATIONS

6

READS

2,284

5 authors, including:



Maheedhar Gedela

University of South Dakota Sanford School of Medicine, United States

45 PUBLICATIONS 30 CITATIONS

SEE PROFILE



Kalyan Potu

Southern Illinois University School of Medicine

21 PUBLICATIONS 26 CITATIONS

SEE PROFILE



Lokesh Jha

Parkview Health Fort Wayne Indiana

51 PUBLICATIONS 165 CITATIONS

SEE PROFILE

Some of the authors of this publication are also working on these related projects:



Pulmonary Embolism Caused by Popliteal Vein Aneurysm: A Case Report. [View project](#)



Bradycardia during Transradial Cardiac Catheterization due to Catheter Manipulation: Resolved by Catheter Removal [View project](#)

A Case of Hepatotoxicity Related to Kombucha Tea Consumption

By Maheedhar Gedela, MD; Kalyan Chakravarthy Potu, MD; Vasantha L. Gali, MD; Kimberlee Alyamany, MD; and Lokesh K. Jha, MD

Abstract

The use of herbal and dietary supplements (HDSs) is widespread and growing due to the popular notion that these products are of natural origins and safe. Kombucha (or “mushroom”) tea is one HDS that is consumed by people for various perceived health benefits. Kombucha tea is a well-known health beverage made by fermenting sweet black tea with a round, flat, gray fungus for a week or longer. There is concern, however, from the evidence of a few case reports currently available, that it may pose life-threatening and/or adverse effects for users.

Introduction

The use of herbal and dietary supplements (HDSs) in developed nations has increased enormously despite awareness of their potential toxicities. Only one-third of HDS consumers reported their use of these products to a health care provider.¹ In the U.S. in 2004, 18.9 percent of adults reported using these products.² Of note, in 1998 an estimated \$4 billion was spent on HDSs.³ There are currently no regulations to give the U.S. Food and Drug Administration (FDA) the authority to review and approve the safety of herbal products.⁴ The clinical presentation of HDS hepatotoxicity can range from mild hepatitis to acute hepatic failure requiring transplantation. Despite such ill effects, people continue to use these supplements widely.

Kombucha (or “mushroom”) tea, also known as Manchurian or Kargasok tea, is a misnomer. The “mushroom” is a symbiotic aggregate of several yeasts and bacteria held together by a thin, permeable membrane.⁵ Supposed benefits of consuming Kombucha tea have included the prevention of cancer, decreased blood pressure, boosting the immune system (especially in human immunodeficiency virus [HIV] patients), relief of arthritis pain, alleviation of constipation, treatment for insomnia, cleansing of the gall bladder, and hair regrowth.⁶ However, no scientific research has validated these claims. Several cases of acute hepatitis and lactic acidosis, in fact, were attributed to its use in the 1990s.⁷ Here, we present a case of cholestatic hepatitis related to the consumption of Kombucha tea that emphasizes the careful evaluation of these products by physicians and stringent scrutiny of their production by regulatory authorities.

Case Presentation

A 58-year-old non-obese female with a medical history

significant for diabetes mellitus and hypothyroidism admitted to our institution with constant epigastric pain of five days' duration associated with nausea. She had clay-colored stool three days prior, but stool had returned to its normal appearance when she presented. At that time, she also noted having dark-colored urine. Additionally, she noted having pruritus and jaundice for the previous three days. She denied experiencing vomiting, hematemesis, heartburn, dysphagia, odynophagia, diarrhea, constipation, hematochezia, mucous in stools, melena, and greasy or fatty stools. The patient had been consuming a significant amount of Kombucha tea for one month prior to her admission.

Following the laboratory evaluation, she was noted as having a disproportionate elevation of alkaline phosphatase with respect to aminotransferases, along with direct bilirubinemia, which is suggestive of a cholestatic pattern (Table 1). Results of serological testing for hepatitis A, hepatitis B, hepatitis C, Epstein-Barr virus, cytomegalovirus, and herpes simplex virus were negative. The patient had normal ferritin, alpha-1-antitrypsin, ceruloplasmin, and coagulation panels. An autoimmune work-up showed normal anti-nuclear antibodies, anti-mitochondrial antibodies, and anti-smooth muscle antibodies. Her hematological markers, electrolyte levels, metabolic profile, thyroid function tests, and lipase values were unremarkable. A right-upper-quadrant ultrasound showed no gallstones or bile duct dilation, and this was confirmed with magnetic resonance cholangiopancreatography.

The patient's abdominal pain was resolved during the hospital course with conservative measures. She underwent a CT-guided liver biopsy that showed moderately active hepatitis with increased eosinophils and bile duct injury without any fibrosis, suggesting drug-induced liver

injury (Figure 1). She was discharged with ursodeoxycholic acid for the cholestatic pattern of liver injury and cholestyramine for itching. She was counseled not to take any herbal supplements and scheduled a follow-up clinic visit in two weeks with liver function tests (LFTs). Her liver biopsy slides were reviewed at the Mayo Clinic as well, and they concurred with the finding of acute drug-induced liver injury. At the patient's two-week clinic follow-up, LFTs were significantly improved (Table 1). Her liver enzymes had normalized by the one-month follow-up visit, so ursodeoxycholic acid was discontinued. Her liver enzymes remained normal one month after discontinuing ursodeoxycholic acid (Table 1).

Discussion

In our patient, the use of Kombucha tea prior to the onset

of symptoms and symptom resolution upon stopping tea consumption suggests a probable causal association with hepatotoxicity. The FDA has not found any pathogenic organisms or hygienic violations in the practices of the commercial manufacturers of this product.⁸ However, there is a clear possibility of contamination with spores from more pathogenic yeast or bacteria, because ingredients used for preparing Kombucha are passed from one user to another.⁷ The PH of tea becomes 1.8 in 24 hours in the brewing phase. For this reason, it should not be prepared or stored in ceramic or lead containers, as toxic constituents can permeate into the tea due to the acidity.

The mechanism underlying the potential toxicity and side effects of Kombucha tea consumption is not clear. More recently, hyperthermia, lactic acidosis, and acute renal

failure were reported within 15 hours of Kombucha tea ingestion in a newly diagnosed, young HIV patient.⁹ In 2004, a case of anti-Jo1 antibody-positive myositis was noted as a consequence of Kombucha tea use.¹⁰ Elevated liver enzymes and the sub-acute onset of an erythematous papular rash were noted in a 53-year-old college professor after drinking a half-cup of Kombucha tea for two weeks. He was followed on an ambulatory basis. His symptoms and lab values were resolved over the next month.⁵ Two middle-aged women from Iowa presented with severe lactic acidosis and respiratory failure after consuming four ounces of home-fermented Kombucha tea for two months in 1995, and one of them died.⁷ However, at least 115 additional individuals in the town had brewed the tea from the same source as those two affected women and tolerated it well, without any ill effects. Also, a 55-year-old alcoholic female presented with jaundice and elevated hepatic enzymes and bilirubin after consuming two glasses of Kombucha tea for two months. After the cessation of tea consumption for the following seven weeks, her laboratory values were normalized.¹¹

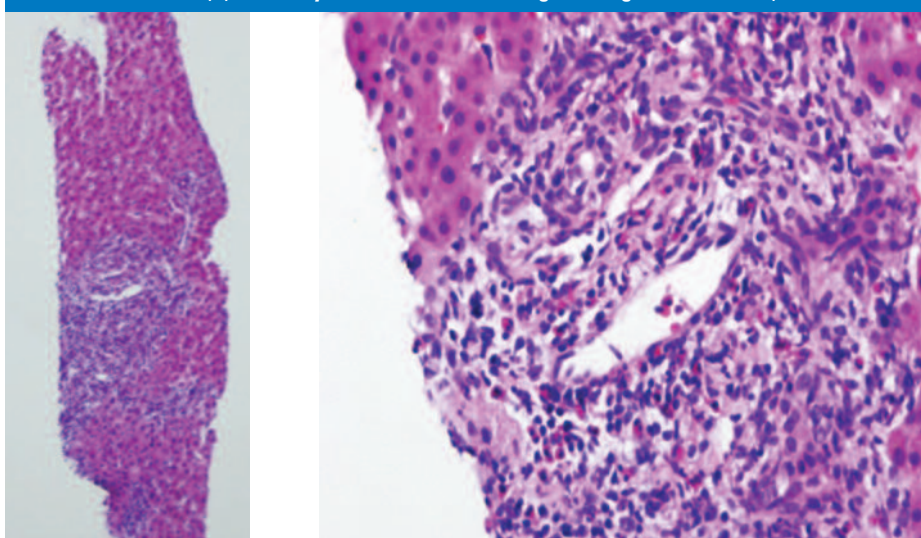
This case serves to remind health

Table 1.

Liver Function Test (normal ranges in parentheses)	On the Day of Admission	On the Day of Discharge	2-Week Follow-Up Visit	1-Month Follow-Up Visit While on Ursodeoxycholic Acid	2-Month Follow-Up Visit Without Ursodeoxycholic Acid
Total Bilirubin (0.0 – 1.3 mg/dL)	4.1	7.6	2.5	1.0	0.6
Direct Bilirubin (0.0 – 0.3mg/dL)	36	6.5			
ALT (11- 66 U/L)	330	314	146	38	37
AST (14- 59 U/L)	141	203	61	25	26
ALP (38 - 126 U/L)	630	908	411	99	69

ALT: Alanine aminotransferase AST: Aspartate aminotransferase ALP: Alkaline phosphatase

Figure 1. Needle biopsy of the liver: (A) a moderate amount of mixed-portal inflammation (hematoxylin and eosin stain, original magnification x 10) and (B) inflammatory cells demonstrate a significant increase in eosinophils with bile duct damage (indicated with an arrow) (hematoxylin and eosin stain, original magnification x 40).



care providers to question all patients regarding complementary and alternative therapies, along with prescription medications, and to caution patients against the consumption of any potentially hepatotoxic supplements. In most instances, even if harmful drug events are recognized, reporting rates are extremely low. Therefore, we advocate for the notification of any adverse health effects related to HDS use to the FDA through the MedWatch spontaneous reporting system at www.fda.gov/medwatch/ or by telephone at 800.332.1088 or 301.738.75537, with the goal of developing tighter regulations regarding HDS manufacturing practices and further research to analyze the chemical compositions and understand hepatotoxic mechanisms in HDSs. We encourage health care providers to search a comprehensive resource (www.livertox.nih.gov/) if there is any suspicion of an HDS causing drug-induced liver injury.

REFERENCES

1. Kennedy J. Herb and supplement use in the US adult population. *Clin Ther.* 2005 Nov;27(11):1847-58. PubMed PMID: 16368456
2. Barnes PM, Powell-Griner E, McFann K, Nahin RL. Complementary and alternative medicine use among adults: United States, 2002. *Adv Data.* 2004 May 27;(343):1-19. PubMed PMID: 15188733
3. Brevoort P. The booming US botanical market: a new overview. *HerbalGram.* 1998;44:33-46
4. Navarro VJ. Herbal and dietary supplement hepatotoxicity. *Semin Liver Dis.* 2009 Nov;29(4):373-82. doi: 10.1055/s-0029-1240006. Epub 2009 Oct 13. Review. PubMed PMID: 19826971.

Please note: Due to limited space, we are unable to list all references. You may contact South Dakota Medicine at 605.336.1965 for a complete listing.

About the Authors:

Maheedhar Gedela, MD, Resident Physician, Department of Internal Medicine; Assistant Professor, Department of Internal Medicine, Sanford Center for Digestive health, University of South Dakota Sanford School of Medicine.

Kalyan Chakravarthy Potu, MD, Resident Physician, Department of Internal Medicine, University of South Dakota Sanford School of Medicine.

Vasantha L Gali, MD, Resident Physician, Department of Pathology; Assistant Professor, Department of Pathology, University of South Dakota Sanford School of Medicine.

Kimberlee Alyamany, MD, Resident Physician, Department of Pathology; Assistant Professor, Department of Pathology, University of South Dakota Sanford School of Medicine.

Lokesh K. Jha, MD, Resident Physician, Department of Internal Medicine; Assistant Professor, Department of Internal Medicine, Sanford Center for Digestive health, University of South Dakota Sanford School of Medicine.

star power.



*The brightest stars
are those that shine
for the benefit
of others.*



Sioux Falls Specialty Hospital is honored and humbled to be the patients' choice for satisfaction. Because of our dedicated people, our personal commitment to our patients and the stellar care we provide, SFSH is the **only hospital** in the Sioux Falls region to receive a 5-star rating in the latest release of the HCAHPS* Survey in all 11 categories including:

- Overall Hospital Rating
- Pain Well Controlled
- Quietness of Hospital Environment
- Would Recommend Hospital

Our high standards of excellence are set for one reason – the benefit of our patients. We couldn't be more proud.



SURGERY | PAIN MANAGEMENT | IMAGING | MIDWEST FAMILY CARE | DIGESTIVE HEALTH

Proud to be Physician Owned and Operated

(605) 334-6730 • sfsh.com

* HCAHPS (Hospital Consumer Assessment of Healthcare Providers and Systems) Survey